

CASE REPORT

Unusual Occurrence of Inguinal Hernia in Raw Area Postdebridement for Fournier Gangrene

¹Jeetendar Paryani, ²Gunvant Rathod, ³Rakesh Makwana, ⁴Ravi Gadani, ⁵Rajesh Patel

ABSTRACT

Fournier gangrene (FG) is an idiopathic spreading necrosis of the scrotum surrounding perineum which may even spread to anterior abdominal wall. The development and fast progression of gangrene can rapidly cause multiple organ failure and death. Because of potential complications, it is important to diagnose the disease process as early as possible.

Management of the condition includes initial resuscitation, combined with broad spectrum intravenous (IV) antibiotics and aggressive debridement, followed by dressing and local management. Once the bed of the wound is prepared, the wound may be covered with split thickness grafts or testicular repositions.

Fournier gangrene is rare but life-threatening disease. Nonetheless, occurrence of another surgically correctable emergency in the same patient can complicate the course of disease and alter the management strategy. The identification and management of such a condition in an open wound pose a diagnostic and therapeutic challenge.

Here, we would like to describe the case, we encountered in our ward (Civil Hospital, Ahmedabad), which developed hernia postdebridement for FG. It presented as swelling in the raw area. The diagnosis was confirmed by investigations and managed with herniorrhaphy as the wound was contaminated. Daily dressing was continued for the raw area. The raw area developed healthy granulation tissue and there were no complications related to hernia surgery during the postoperative course. Patient then underwent testis reposition in the thigh pouch as well as coverage of raw area with split thickness graft. The uptake was healthy, and patient was discharged without any complication.

Keywords: Fournier gangrene, Postdebridement inguinal hernia, Herniorrhaphy.

How to cite this article: Paryani J, Rathod G, Makwana R, Gadani R, Patel R. Unusual Occurrence of Inguinal Hernia in Raw Area Postdebridement for Fournier Gangrene. *J Trauma Crit Care Emerg Surg* 2014;3(1):33-36.

Source of support: Nil

Conflict of interest: None

RESUMEN

La gangrena de Fournier (FG) es una necrosis difusión idiopática de el escroto que rodea el perineo que puede incluso

extenderse a pared abdominal anterior. El desarrollo y la progresión rápida de gangrena puede causar rápidamente un fallo multiorgánico y la muerte. Debido a las complicaciones potenciales, es importante para diagnosticar el proceso de la enfermedad tan pronto como sea posible.

Gestión de la condición incluye la reanimación inicial, combinada con la amplia intravenosa (IV) de espectro antibióticos y el desbridamiento agresivo, seguido de vestir y locales gestión. Una vez que el lecho de la herida se prepara, la herida pueden ser cubiertos con los injertos de espesor parcial o reposiciones testiculares.

La gangrena de Fournier es rara, pero la enfermedad que amenaza la vida. Sin embargo, la aparición de otra corregible quirúrgicamente de emergencia en el mismo paciente puede complicar el curso de enfermedad y alterar la estrategia de gestión. La identificación y la gestión de una condición tal en una herida abierta pose un reto diagnóstico y terapéutico.

Aquí, nos gustaría describir el caso, nos encontramos en nuestro barrio (Hospital Civil, Ahmedabad), que desarrolló una hernia postdebridement de gangrena de Fournier. Se presenta como hinchazón en el área en bruto. El diagnóstico fue confirmado por las investigaciones y gestionado con herniorrafia como la herida estaba contaminada. Diario se continuó vestidor para el área de crudo. El área cruda desarrollado tejido de granulación saludable y no hubo complicaciones relacionadas para la cirugía de la hernia durante el postoperatorio. Paciente luego reposición testículo se sometió en la bolsa del muslo, así como la cobertura del área de crudo con injerto de espesor parcial. La absorción era sano, y paciente fue dado de alta sin ningún tipo de complicación.

Palabras claves: Hernia después de desbridamiento, Hernia inguinal, La reparación de la hernia, Gangrena fourinier.

INTRODUCTION

Fournier gangrene (FG) is a rapidly developing and spreading necrosis and gangrene of the skin and subcutaneous tissues of the scrotum, and surrounding perineum, or even reaching up to the anterior abdominal wall.¹⁻⁴ It was first described by Jean Alfred Fournier. The disease was considered to be idiopathic initially, but now it is well known to be secondary to some urinary, perineal or soft tissue pathology.^{2,3} It is predisposed mainly by diabetes mellitus, alcoholism, paraplegia, old age and renal insufficiency.^{2,3} But in many cases, the predisposing factor may not be found. The patient presents with rapidly deteriorating course which may progress to fulminant multiorgan failure.¹⁻³ Treatment includes early recognition, aggressive debridement of the necrotic area and oxygenation, intensive care unit (ICU) admission, broad spectrum antibiotics and supportive care.¹⁻⁴

¹Senior Resident, ²Professor, ³⁻⁵Assistant Professor

¹⁻⁵Department of Surgery, BJ Medical College, Ahmedabad Gujarat, India

Corresponding Author: Jeetendar Paryani, Senior Resident Department of Surgery, BJ Medical College, Ahmedabad Gujarat, India, Phone: 07926421271, e-mail: paryani.jeetu@gmail.com

Usually, the debridement of the region gives rise to raw area which requires aggressive management that may include subsequent trips to operation theaters for debridement. These raw areas are then managed by dressing with appropriate agents.¹ Managements of the raw area may be complicated by some surgical events, such as development of inguinal hernia in the groin wound. Identification of such events is very difficult, because the area is often covered with dressing and is open to view only once or twice a day. Also, due to the agents used in dressing the sac tends to granulate and merge with raw area. Failure to identify such a hernia which may contain bowel may result in development of fecal fistula.

After identification, management of such case is a difficult task. Contaminated surrounding, covering of granulation tissue over sac, adhesions of sac with the raw area, and absence of skin cover, and so on make the surgery extremely tedious and difficult to execute.

Here, we describe such a case that developed inguinal hernia during the postoperative course for debridement done for FG in our ward (Civil Hospital, Ahmedabad).

CASE REPORT

A 40-year-old male presented with history of scrotal swelling since 7 days, retention of urine since 3 days and history of high grade fever, and altered sensorium since 1 day. Patient also had history of burning micturition on and off since 3 months. He was a known diabetic patient taking oral hypoglycemic drugs for the same since last 2 years. He did not have history of any operation, anesthesia, and drug allergy.

On examination, he was febrile and tachypneic with pulse rate of 120/min, blood pressure of 86/50 mm Hg. Local examination revealed extensive swelling and gangrene of scrotum and penile skin, extending into the anterior abdominal wall up to lower 1/3rd of abdomen. It was foul smelling with areas of pus discharge. Urinary meatus was not visible and bladder was distended.

Investigations revealed random blood sugar 382 mg/dl and total white blood cell (WBC) count 21,000/mm. Serum urea and creatinine was elevated (S. urea—143 mg/dl, S. creatinine—2.01 mg%).

Initial resuscitation was carried out by inserting two wide bore needles and intravenous (IV) fluids were administered. Since per-urethral catheterization was not possible due to sloughed urethra, suprapubic catheterization was done and urine was drained. Broad-spectrum antibiotics were administered and patient was taken to operation theater after the vitals were settled. Debridement was carried out under general anesthesia to remove the devitalized tissue. This created a raw area extending from lower part of abdomen just below the suprapubic catheter site to bare the entire penis and testis. Postoperatively, patient was shifted to the ICU for close cardiopulmonary monitoring and strict glycemic control.

Patient improved after the procedure and vitals were stable. Total count reduced to 15,000/mm³ on postoperative day 2 and 9,600/mm³ on postoperative day 4. Serum creatinine was normalized on postoperative day 4. Local condition of the wound improved over a period of 8 to 10 days.

At the time of dressing on postoperative day 10, presence of a pink swelling of size about 2 × 2 cm² on the raw area just above the pubic tubercle on the right side was noticed. Initially, the diagnosis could not be established but in the following 2 days the swelling enlarged to about size of 4 × 3 cm². The size of swelling increased on coughing and was reducible. So, initial diagnosis of right-sided inguinal hernia was made. The diagnosis was confirmed on ultrasound of the local part and sac was found to contain bowel.

The patient was kept conservatively and Vaseline gauze was used for dressing subsequently to prevent damage to the sac. But since the hernia contained bowel loops, a decision to operate the patient was taken to prevent injury to the sac and the occurrence of fecal fistula (Fig. 1).

Patient was operated electively on postoperative day 13. Patient was given spinal anesthesia. Painting and draping

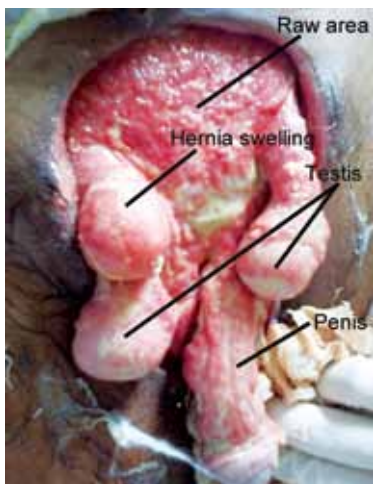


Fig. 1: Preoperative view

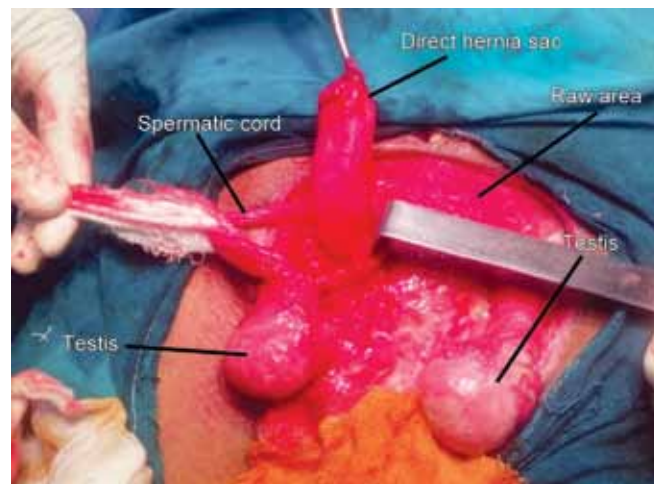


Fig. 2: Initial view during operation

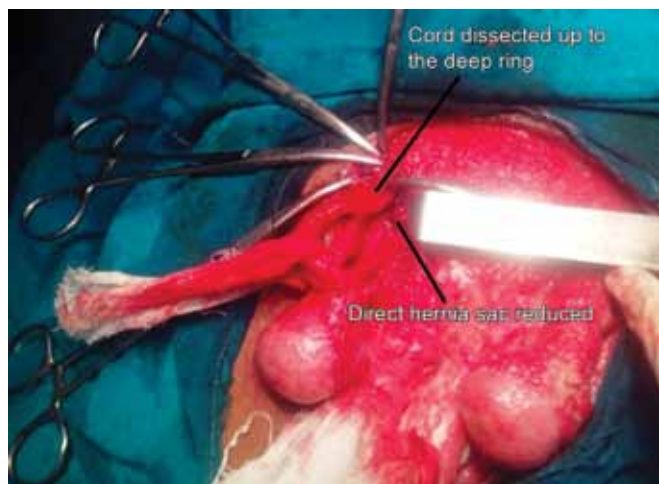


Fig. 3: After reduction of hernia sac

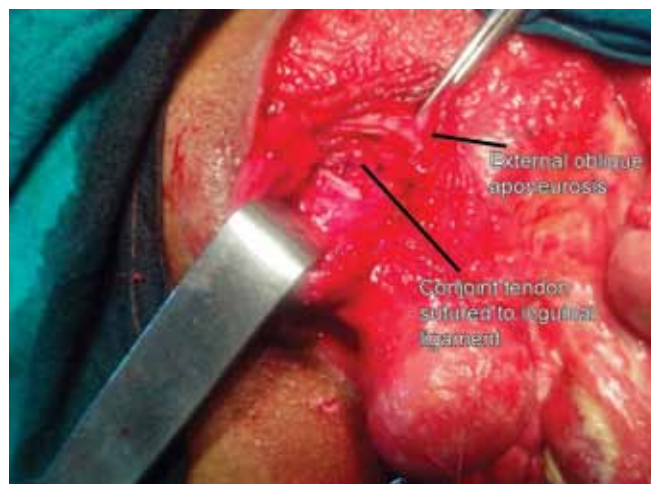


Fig. 4: Postherniorrhaphy

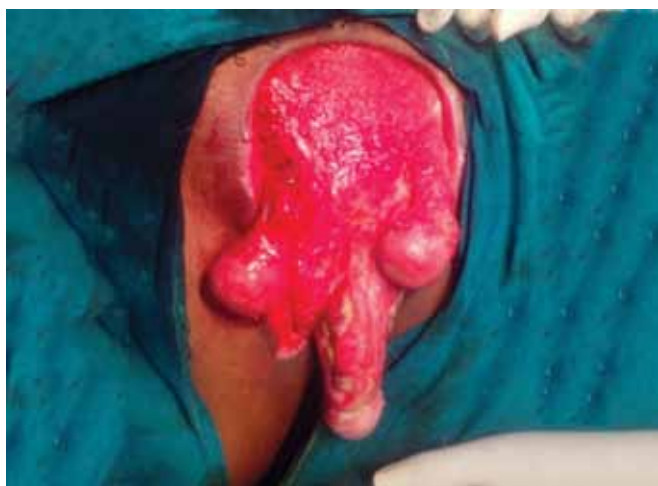

Fig. 5: Final postoperative picture

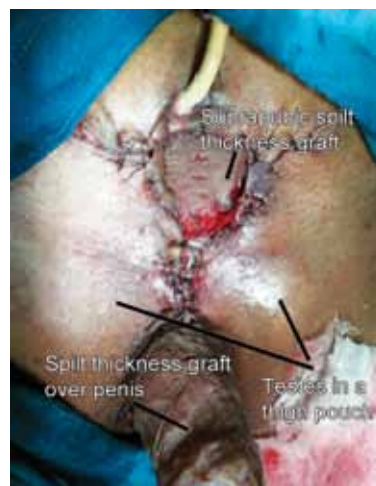

Fig. 6: Final outcome postcoverage

was done in usual manner. Sac was held by Babcock's forceps and freed for surrounding adhesions from it to raw area. Spermatic cord was identified from overhanging testis. Sac was lying medial to cord thus being a direct hernia sac (Fig. 2). External oblique aponeurosis which was covered with granulation tissue was cut. Sac was reduced (Fig. 3).

Cord was dissected up to the deep ring and no indirect hernia was found. Posterior wall plication was done using polypropylene sutures (2-0) with continuous sutures. Because of the presence of gross contamination in the perioperative area, a decision to perform a herniorrhaphy was taken. Conjoint tendon was sutured to reflected edge of inguinal ligament using interrupted polypropylene (2-0) sutures starting from the pubic tubercle and extending laterally (Fig. 4). External oblique aponeurosis was closed with polypropylene (2-0) interrupted sutures. The raw area was then dressed with povidone-iodine solution, and then patient was shifted to the ward after anesthetist's advice (Fig. 5).

Postoperative course was uneventful. Patient was dressed once daily using povidone iodine solution. There were no complications related to hernia surgery. At postoperative day 21,

there was no evidence of any recurrence. The raw area was healthy. Daily dressing was done. Patient was discharged on postoperative day 30. After 10 days of discharge, patient presented for follow-up. He was admitted for repositioning of testes and coverage of the raw area as the wound was healthy. He underwent surgery where the testes were repositioned into the thigh pouch and suprapubic and penile raw area was covered with split thickness graft taken from the thigh (Fig. 6). There were no postoperative complications.

DISCUSSION

Fournier gangrene is considered to be necrotizing fasciitis of the scrotum and the surrounding skin and superficial fascia.¹⁻⁴ It is an emergency condition characterized by high rates of mortality if not identified and treated early. Although described classically as idiopathic is mostly to urologic and perianal etiologies.^{2,3}

It is polymicrobial in nature which is mostly the combination of Gram positive and Gram negative bacteria along with the anaerobes although some cases do report a combination of group a *Streptococcus* with *Staphylococcus aureus*.²

Predisposing factors are diabetes, alcoholism, immobility, and renal insufficiency.¹⁻⁴ Mostly, the foci of origin is from the gastrointestinal or genitourinary tract or the skin.³

Patient presents with features of acute spreading necrosis and surrounding skin genital and scrotal pain are out of proportion to the swelling. The swelling erythema and discolorations of the local area are the most common manifestations of the disease. Patients may also present with the features of septicemia and multiple organ failure.

Management of the condition starts from is early diagnosis. Fluid resuscitation and ICU care with cardiopulmonary monitoring forms the initial management. Aggressive debridement with attempt to remove all of devitalized tissue forms the keystone of the management of Fournier's gangrene. Broad-spectrum antibiotics should be instituted which include third generation cephalosporins, with adequate coverage for the anaerobes.¹⁻⁴

The debridement done for conditions leads to formation of raw area which is covered by dressing. The raw area may require multiple debridements under anesthesia. The dressings may be dry, wet, or use tropical agents. Vacuum-assisted devices have been successfully used in the management of local wound of Fournier gangrene. When the healthy granulations appear over the wound, the coverage is provided by split thickness grafts. Also, the testis may be repositioned into subcutaneous thigh pouches.

Management of local wounds may be complicated by surgical events and emergencies. Guzzo et al⁵ described the occurrence of incarnated hernia in their patients with wound of Fournier gangrene. Our patient did not develop incarnated hernia but developed uncomplicated direct hernia in the wound. Since the presentation of asymptomatic hernia was after 10 days we do not believe that aggressive debridement was the cause of hernia rather an incidental occurrence. But the sac contained bowel so there was risk of occurrence of fecal fistula, therefore, decision to do hernia repair was taken.

Since the repair had to be done in contaminated setting, conventional meshes could not be used. Guzzo et al⁵ used

biological meshes in three patients in similar setting. Biological meshes can be used in such contaminated fields.⁶ But in our setting, due to high cost and unavailability of biological meshes, only herniorrhaphy was done.

There were no local complications or recurrence on postoperative day 21.

SUMMARY

The wound of Fournier gangrene may be complicated by the occurrence of hernia. The raw area makes it difficult to identify the hernia which may be present. High degree of suspicion is required for diagnosis of such an event. Early operative intervention ensures that hernia does not become complicated. The surgery can be difficult and tedious because of bare structures and granulation tissue. The options of repair depend on the surgeon choice. Biological meshes may be used but they are expensive. Surveillance and careful dressing may be required for long term for the patient.

REFERENCES

1. Hohenfellner M, Santucci RA, editors. *Emergencies in Urology*. New York: Springer; 2007.p.659.
2. Singam P, Wei KT, Ruffey A, Lee J, Chou TG. Fournier's gangrene: a case of neglected symptoms with devastating physical loss. *Malays J Med Sci* 2012 Jul;19(3):81-84.
3. Hota PK. Fournier's gangrene: Report of two cases. *Case Reports in Emergency Medicine is a Peer-reviewed, Open access Journal* 2012 (2012): Article ID 984195.
4. Verma S, Sayana A, Kala S, Rai S. Evaluation of the utility of the Fournier's gangrene severity index in the management of Fournier's gangrene in north India: a multicentre retrospective study. *J Cutan Aesthet Surg* 2012 Oct;5(4):273-276.
5. Guzzo JL, Bochicchio GV, Henry S, Keller E, Sclea TM. Incarcerated inguinal hernia in the presence of Fournier's gangrene: A novel approach to a complex problem. *Am Surg* 2007 Jan;73(1):93-95.
6. Cavallaro A, LO Menzo E, Di Vita M, Zanghi A, Cavallaro V, Verour PF, Cappellani A. Use of biological meshes for abdominal wall reconstruction in highly contaminated fields. *World J Gastroenterol* 2010 Apr 21;16(15):1928-1933.