

## CASE REPORT

# Bilateral Traumatic Hemorrhage of the Basal Ganglia with Diffuse Axonal Injury: A Case Report and Review of Literature

<sup>1</sup>Shrikant V Rege, <sup>2</sup>Sharadendu Narayan, <sup>3</sup>Harshad Patil, <sup>4</sup>Jitendra Tadghare

## ABSTRACT

Traumatic brain injury is a major public health problem, and is the leading cause of mortality, morbidity, and disability in children and young adults, especially young men (15–35 years). Bilateral traumatic basal ganglia hemorrhage (TBGH) is a rare entity with less than eight cases reported in literature. The mechanism of this injury is not well understood, and various theories based on autopsy findings have been proposed to explain this injury. Outcome of TBGH is usually favorable, unless associated with other concomitant neuroparenchymal injuries. A case of traumatic bilateral basal ganglia hematoma has been discussed here with review of available literature on the subject.

**Keywords:** Basal ganglia hemorrhage, Bilateral, Diffuse axonal injury, Traumatic.

**How to cite this article:** Rege SV, Narayan S, Patil H, Tadghare J. Bilateral Traumatic Hemorrhage of the Basal Ganglia with Diffuse Axonal Injury: A Case Report and Review of Literature. *Panam J Trauma Crit Care Emerg Surg* 2017;6(1):49-51.

**Source of support:** Nil

**Conflict of interest:** None

## RESUMO

La lesión cerebral traumática es un importante problema de salud pública, y es la principal causa de mortalidad, morbilidad y discapacidad en niños y adultos jóvenes, especialmente los hombres jóvenes (de 15 a 35 años). Traumática bilateral de ganglios basales TBGH (hemorragia) es una entidad rara, con menos de ocho casos reportados en la literatura. El mecanismo de esta lesión no es bien entendido, y diversas teorías basadas en la autopsia indings han sido propuestas para explicar este tipo de lesión. Resultados de TBGH generalmente es favorable, a menos que estén asociados con otras lesiones neuroparenchymal concomitante. Un caso de hematoma ganglios basales bilaterales traumáticas se ha debatido aquí con una revisión de la literatura disponible sobre el tema.

**Palabras claves:** Bilateral, lesión axonal difusa, Hemorragia de ganglios basales, Traumática.

<sup>1</sup>Professor and Head, <sup>2-4</sup>Senior Resident

<sup>1-4</sup>Department of Neurosurgery, Sri Aurobindo Medical College and Post Graduate Institute, Indore, Madhya Pradesh, India

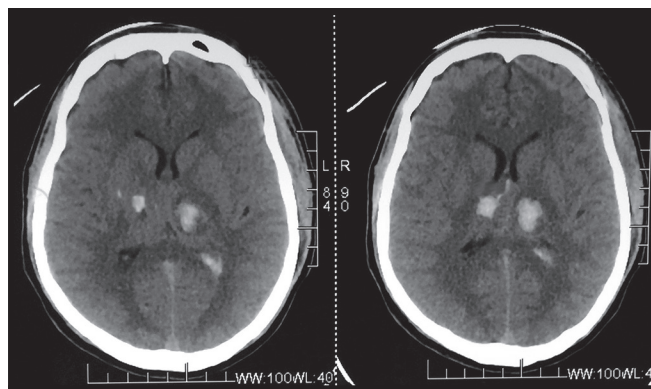
**Corresponding Author:** Sharadendu Narayan, Senior Resident, Department of Neurosurgery, Sri Aurobindo Medical College and Post Graduate Institute, Indore, Madhya Pradesh India, Phone: +917389992400, e-mail: sharad\_jsr@yahoo.com

## INTRODUCTION

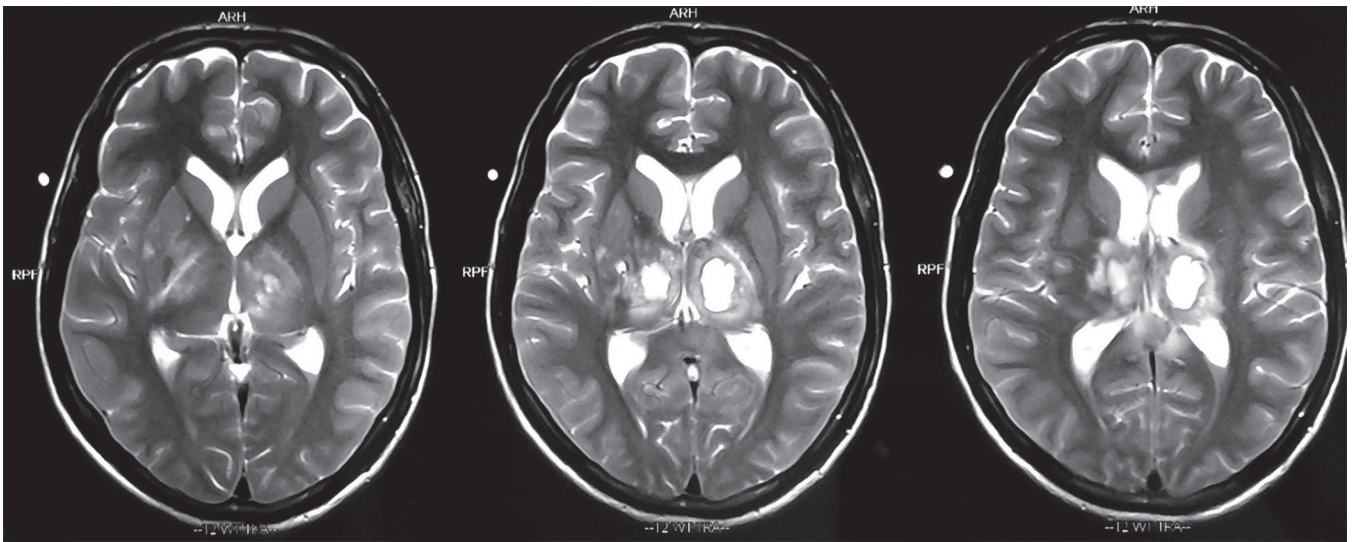
Traumatic basal ganglia hemorrhage (TBGH) is defined as a hemorrhagic lesion in the basal ganglia and its surrounding structures, namely internal capsule and thalamus.<sup>1-3</sup> The incidence of TBGH is between 2.4 and 3% after a closed head injury.<sup>1-3</sup> Autopsy studies suggest a far greater incidence rate of 10 to 12%.<sup>1,2</sup> It is classified based on diameter as small (size <2 cm) and large (size >2 cm).<sup>2,4</sup> The prognosis of patients with isolated TBGH is good; however, bilateral TBGH is usually associated with other brain injuries and heralds a poor outcome.

## CASE REPORT

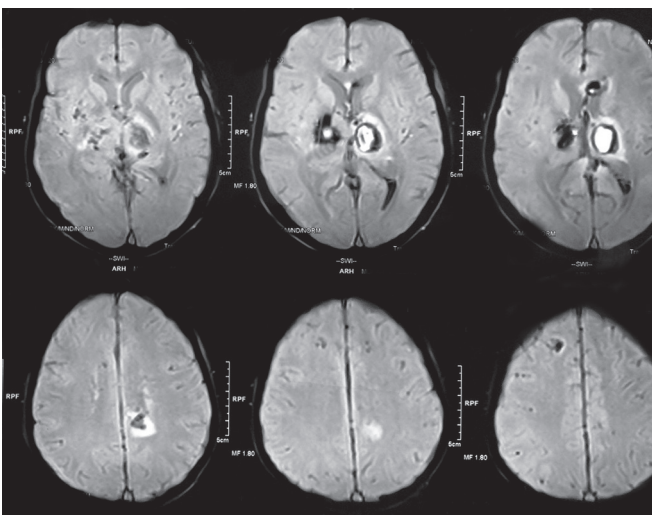
A 20-year-male presented to the casualty department after allegedly being hit by a speeding car while crossing the road. There was associated loss of consciousness with one to two episodes of vomiting. There was no associated injury noted in the other systems. Patient was accompanied by relatives who gave no history of substance abuse, chronic medical illnesses, or bleeding diathesis. Patient Glasgow Coma Scale (GCS) at admission was 5/15 with bilaterally equal and sluggish reacting pupils to light and right hemiparesis. Patient was intubated and shifted for an urgent computed tomography (CT) brain scan. The CT scan was suggestive of bilateral basal ganglia hematoma 1.8 × 1.5 cm on left and 1.2 × 1 cm on right side with intraventricular extension of bleeding in lateral ventricle (Fig. 1). Patient was admitted in intensive care unit, and he was started on antiedema and antiepileptic medications.



**Fig. 1:** The CT brain scan showing a bilateral basal ganglia hemorrhage and intraventricular extension of bleed



**Fig. 2:** The MRI brain T2-weighted sequence s/o bilateral basal ganglia hemorrhage



**Fig. 3:** The MRI brain susceptibility weighted imaging weighted sequence s/o bilateral basal ganglia hemorrhage with DAI

The lab investigations including bleeding time, clotting time, and prothrombin time were within normal range. Patient had a gradual improvement in GCS and had a GCS of E3VtM4 on the 5th day. A magnetic resonance imaging (MRI) of the brain was performed on the 5th day, which revealed presence of acute to subacute bilateral basal ganglia hematoma with minimal perilesional edema and extension of hematoma in lateral ventricle. Multiple small punctate hemorrhagic areas noted in bilateral hippocampi, brainstem, and corpus callosum were suggestive of diffuse axonal injury (Figs 2 and 3). The MRI angiogram did not reveal any vascular abnormalities. Patient was shifted to ward and discharged after 20 days after closure of tracheostomy with a GCS of E3V3M5.

## DISCUSSION

The TBGH is a rare entity with an incidence rate of <3% in closed head injuries.<sup>1-3</sup> The patients with TBGH

have increased incidence of coagulation abnormalities, diffuse axonal injury, intraventricular hemorrhage, and intra-/extraaxial bleed and have a correspondingly poor outcome. Since basal ganglia region is predisposed to hypertensive bleed, at times, it becomes difficult to distinguish between hypertensive and traumatic hemorrhage. It has been suggested that the TBGHs are small, multiple, rarely bilateral, located in the zone of lentiform nucleus and external capsule, whereas spontaneous hemorrhages are large, solitary, and located mainly in the region of thalamus and internal capsule.<sup>1,5</sup> In a known hypertensive patient with head injury and findings of basal ganglia bleed, it is imperative to ascertain the sequence of events. This may be a medicolegal issue; as to whether the patient had a spontaneous basal ganglia bleed leading to the subsequent head injury or it was the head injury, which caused the basal ganglia hematoma.

This rare entity has been previously reported in literature by Yanaka et al<sup>6</sup> (2 cases), Jang et al<sup>7</sup> (1 case), Kaushal et al<sup>8</sup> (1 case), Bhargava et al<sup>1</sup> (1 case), and Pandey et al<sup>9</sup> (1 case). Jain et al<sup>10</sup> have mentioned the only case of large bilateral TBGH with a fully conscious patient unlike the above-stated reports where the patients all had a poor GCS.

The exact pathogenesis of basal ganglia hematoma is unclear; however, it is suggested that when a strong impact occurs over the vertex, forehead, or occipital region, the shearing force causes the brain to be displaced through the tentorial notch. This results in stretching and tearing of the vessels resulting in hematoma.<sup>2</sup> The sudden acceleration/deceleration forces at the time of injury result in shearing strain over the lenticulostriate and anterior choroidal vessels leading to bleeding. Mosberg and Lindenberg,<sup>4</sup> in an autopsy of fatal head injury patient, demonstrated massive hematoma in the

pallidum and ruptured twig of the anterior choroidal artery. Fujioka et al<sup>11</sup> have demonstrated traumatic dissection of the middle cerebral artery causing hemorrhage and infarction in the basal ganglia and thalamus. Very often, the deeply located TBGHs are seen to be associated with coup and countercoup injuries, thus suggesting that these may be intermediary contusions.<sup>9</sup>

Various surgical options have been used for these patients; CT-guided stereotaxic aspiration, ultrasound-guided aspiration, and open surgery. Boto et al<sup>12</sup> advised surgical evacuation of all lesions with volume >25 mL; however, poor outcome was noted in most of these patients. Boto et al noted that 84% of surgically managed patients had an unfavorable outcome. Kumar et al<sup>5</sup> noted improvement in all patients managed conservatively. Kimura et al,<sup>13</sup> Katz et al,<sup>3</sup> and Jang et al<sup>7</sup> have also reported favorable outcomes for TBGH with conservative management. Surgical evacuation entails approach to the hematoma via the thalamoganglionic region, leading to further damage of the eloquent areas resulting in possible poor outcome.

In our patient, there was a clear history of trauma with no antecedent history of preexisting medical illnesses and bleeding diathesis, thus the bilateral basal ganglia bleed seen on CT/MRI scans was traumatic in nature. Our patient had a GCS of 5/15 at presentation, suggesting a severe traumatic head injury. Radiological imaging suggested bilateral TBGH with intraventricular extension of bleed and diffuse axonal injury. As our patient had small bilateral TBGH with volume <25 mL and showed gradual improvement of GCS with medical management, he was managed conservatively. The patient, however, did not become fully conscious at the time of discharge.

## CONCLUSION

Bilateral TBGH is a rare entity with very few cases reported in literature. The mechanism of occurrence of TBGH is not well understood; it is hypothesized to be occurring following shear forces on the lenticulostriate and anterior choroidal arteries. The TBGH can be managed conservatively in most of the patients with smaller hematomas. Prognosis of TBGH is variable; it has a favorable

outcome if it presents as an isolated injury without other neuroparenchymal injuries.

## REFERENCES

1. Bhargava P, Grewal SS, Gupta B, Jain V, Sobti H. Traumatic bilateral basal ganglia hematoma: a report of two cases. *Asian J Neurosurg* 2012 Jul;7(3):147-150.
2. Adams JH, Doyle D, Graham DI, Lawrence AE, McLellan DR. Deep intracerebral (basal ganglia) haematomas in fatal non-missile head injury in man. *J Neurol Neurosurg Psychiatry* 1986 Sep;49(9):1039-1043.
3. Katz DI, Alexander MP, Seliger GM, Bellas DN. Traumatic basal ganglia hemorrhage: clinicopathologic features and outcome. *Neurology* 1989 Jul;39(7):897-904.
4. Mosberg WH, Lindenberg R. Traumatic hemorrhage from the anterior choroidal artery. *J Neurosurg* 1959 Mar;16(2):209-221.
5. Kumar S, Jha D, Abbey P, Mishra V, Handa A. Outcome of traumatic basal ganglia hemorrhage. *Internet J Neurosurg* 2009;6(1).
6. Yanaka K, Egashira T, Maki Y, Takano S, Okazaki M, Matsumaru Y, Kamezaki T, Ono Y, Nose T. Bilateral traumatic hemorrhage in the basal ganglia: report of two cases. *No Shinkei Geka* 1991 Apr;19(4):369-373.
7. Jang KJ, Jwa CS, Kim KH, Kang JK. Bilateral traumatic hemorrhage of the basal ganglia. *J Korean Neurosurg Soc* 2007 Apr;41(4):272-274.
8. Kaushal R, Kataria R, Gupta A, Sinha V. Traumatic bilateral (mirror image) basal ganglia bleed. *Indian J Neurotrauma* 2011 Dec;8(2):109-110.
9. Pandey N, Mahapatra A, Singh PK. Bilateral large traumatic hemorrhage of the basal ganglion. *Asian J Neurosurg* 2014 Oct-Dec;9(4):240.
10. Jain SK, Sundar IV, Sharma V, Prasanna KL, Kulwal G, Tiwari RN. Bilateral large traumatic basal ganglia haemorrhage in a conscious adult: a rare case report. *Brain Inj* 2013;27(4):500-503.
11. Fujioka M, Maeda Y, Okuchi K, Kagoshima T, Taoka T. Secondary change in the substantia nigra induced by incomplete infarct and minor hemorrhage in the basal ganglia due to traumatic middle cerebral arterial dissection. *Stroke* 1999 Sep;30(9):1975-1977.
12. Boto GR, Lobato RD, Rivas JJ, Gomez PA, de la Lama A, Lagares A. Basal ganglia hematomas in severely head injured patients: clinico-radiological analysis of 37 cases. *J Neurosurg* 2001 Feb;94(2):224-232.
13. Kimura M, Sobata E, Suzuki S, Nonogaki Y, Iwabuchi T. Traumatic hematoma in the basal ganglia (caudate) with favorable prognosis: report of two cases. *No Shinkei Geka* 1994 Feb;22(2):155-158.