

CASE REPORT

Non-traumatic Resuscitative Thoracotomy

¹Rafael Andrade-Alegre, ²Saturnino Domínguez

RESUMEN

La toracotomía de resucitación es un procedimiento heroico que generalmente se asocia al trauma. Este procedimiento quirúrgico también puede salvar vidas en emergencias no traumáticas. Presentamos el caso de un paciente sometido a toracotomía de resucitación después de desarrollar paro cardíaco asociado a hemotórax masivo durante un procedimiento endovascular.

Palabras clave: Emergencia, Hemotórax, No traumática, Toracotomía de resucitación.

ABSTRACT

Resuscitative thoracotomy (RT) is a heroic procedure that is generally associated with trauma. This surgical procedure may also save lives in non-trauma-related emergencies. We present the case of a patient who underwent resuscitative thoracotomy after developing cardiac arrest associated with massive hemothorax during an endovascular procedure.

Keywords: Emergency, Hemothorax, Non-traumatic, Resuscitative thoracotomy.

How to cite this article: Andrade-Alegre R, Domínguez S. Non-traumatic Resuscitative Thoracotomy. *Panam J Trauma Crit Care Emerg Surg* 2018;7(3):224-226.

Source of support: Nil

Conflict of interest: None

INTRODUCTION

The use of RT for patients with cardiac arrest after thoracic trauma has been described since the 1960s. In 1967, Ben Taub Hospital in Houston reported using RT for moribund patients with penetrating cardiac trauma.¹ Currently, there are algorithms for the performance of RT outside the hospital by pre-hospital clinicians. However, thoracotomy for non-traumatic cardiac arrest is rarely performed outside of operating rooms and intensive care units.² Here, we present the case of a patient who underwent RT after developing cardiac arrest associated with massive hemothorax during an endovascular procedure.

CASE REPORT

A 36-year-old male with a history of hypertension and chronic renal failure was taken to the vascular angiography suite for the placement of a tunneled catheter for hemodialysis. During the procedure, the patient presented with dyspnea, diaphoresis, and psychomotor agitation. There was diminished air entry into the right chest. Fluoroscopic images were taken, and the right hemothorax was noticed, with extravasation of the contrast media at the level of the entrance of the superior vena cava to the right atrium (Fig. 1A). A chest tube was inserted, and 1200 mL of blood was drained. Orotracheal intubation was performed, and the patient was reanimated. Despite these procedures, the patient presented with two cardiac arrests that were verified clinically and on cardiac monitors. He responded to conventional cardiopulmonary resuscitation (CPR). The thoracic surgery section was immediately called in for consultation. Given the impossibility of moving the patient from the vascular angiography suite, right anterolateral thoracotomy was performed. A total of 800 mL of blood and blood clots was removed. During this procedure, the patient exhibited a third cardiac arrest. Left anterolateral thoracotomy was then performed, the pericardium was incised, and the direct cardiac massage was started. The thoracic aorta was also clamped for 15 minutes. The patient's pulse rate and blood pressure recovered. There was no significant injury in the right chest. The relevant lesion was likely a puncture produced by the guide for the catheter system. Thoracotomies were closed in the usual manner (Fig. 1B). He required mechanical ventilation for 9 days and was neurologically intact when he was discharged home on a

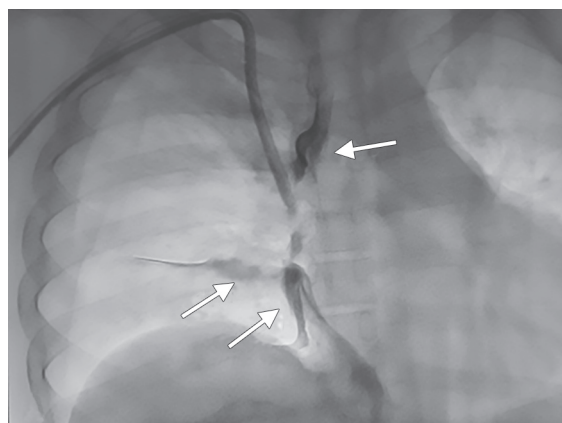


Fig. 1A: Fluoroscopic image. Arrows show the extravasation of contrast media. Right hemothorax is present

¹Chief Thoracic Surgeon ²Resident General

^{1,2}Department of Surgery, Santo Tomás Hospital, Panamá

Corresponding Author: Rafael Andrade-Alegre, Chief Thoracic Surgeon, Department of Surgery, Santo Tomás Hospital, Panamá, e-mail: toravasc@cwpanama.net

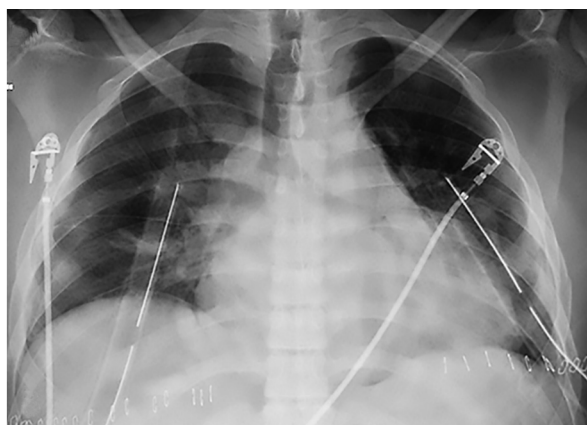


Fig. 1B: Postoperative X-ray image. Chest tubes and skin staples are evident

postoperative day 16 (Fig. 2A). At follow-up 5 months after the described event, the patient was completely recovered and was attending the hemodialysis center on a regular basis (Fig. 2B).

DISCUSSION

The use of RT for non-trauma cases is not a novel concept. In 1901, the Norwegian physician Kristian Igelsrud was the first physician to perform successful resuscitation from cardiac arrest using open-chest compressions in a patient who experienced arrest during an elective hysterectomy.³ This method remained the dominant procedure for CPR for more than 50 years until the 1960s, when closed CPR became the gold standard for both laymen on the street and resuscitation specialists.⁴ However, numerous animal studies have demonstrated improved aortic and coronary perfusion pressures for open CPR compared with closed CPR.⁵ The few human studies in which hemodynamic parameters have been reported have confirmed these animal study findings. In 1995, in the context of a non-traumatic cardiac arrest in human patients, Boczar et al.⁶ demonstrated the extent to which coronary perfusion pressures increased after left anterolateral thoracotomy

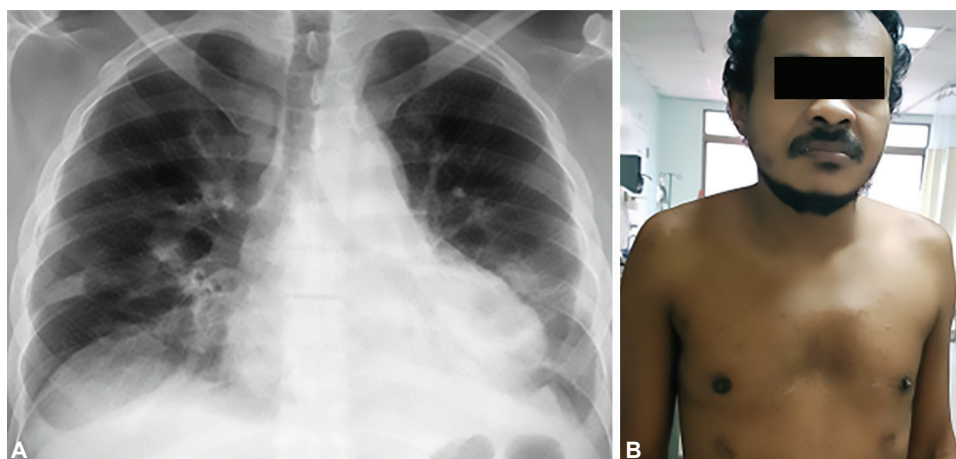
followed by open chest direct cardiac compressions. They found that open cardiac massage was more efficient than closed CPR because the former process generates a steeper gradient of coronary perfusion.

Our patient presented with cardiac arrests and without the possibility of being transferred to a formal operating room; therefore, he was operated on while in a vascular stretcher, with the expected limitations imposed by this environment. A right thoracotomy was performed to evacuate hemothorax and repair the injury, and left thoracotomy was performed to provide direct cardiac massage and clamp the thoracic aorta.

As reported by Fairman and Edmunds⁷ in 1980, cardiac centers have protocols for emergency thoracotomy when cardiac surgery patients develop cardiac arrest during the postoperative period. This approach has continued to evolve over time, with good results.⁸ Now may be the moment to revisit thoracotomy and open cardiac massage and attempt to identify the role of this procedure in non-traumatic cardiac arrest in hospitals. The incorporation of RT algorithms may improve outcomes. Two aspects of paramount importance need to be addressed. The first issue is the selection of suitable patients for RT, given that it is well known that such specialized interventions require a perfectly trained medical team and complex logistics. Second, hospitals would need to develop guidelines and protocols to allow personnel and equipment to be readily available for RT when needed. It is our opinion that saving lives with RT, as occurred in our case, validates these efforts and would represent a step forward in CPR.

ACKNOWLEDGMENT

The first author, as a member of the National System for Research (SNI) and the National Secretariat for Science, Technology, and Innovation (SENACYT), received financial support for this case report.



Figs 2A and B: (A) X-ray image on postoperative day 10. Chest drains have been removed. (B) Photograph of the patient 5 months after surgery

REFERENCES

1. Beall AC Jr, Diethrich EB, Cooley DA, DeBakey ME. Surgical management of penetrating cardiovascular trauma. *South Med J*. 1967;60:698-704.
2. Kornhall DK, Doven T. Resuscitative thoracotomies and open chest cardiac compressions in non traumatic cardiac arrest. *World J Emerg Surg* 2014;9:54.
3. Cooper JA, Cooper JD, Cooper JM. Cardiopulmonary resuscitation: history, current practice, and future direction. *Circulation* 2006;114:2839-2849.
4. Kouwenhoven WB, Ing, Jude JR, Knickerbocker GG. Closed-chest cardiac massage. *JAMA* 1960;7:1064-1067.
5. Kern KB, Sanders AB, Ewy GA. Open-chest cardiac massage after closed-chest compression in a canine model: when to intervene. *Resuscitation* 1987;15:51-57.
6. Boczar ME, Howard MA, Rivers EP, Martin GB, Horst HM, Lewandoski C, et al. A technique revisited: hemodynamic comparison of closed–an open–cardiac massage during human cardiopulmonary resuscitation. *Crit Care Med* 1995;23:498-503.
7. Fairman RM, Edmunds LH. Emergency thoracotomy in the surgical intensive care unit after cardiac operations. *Ann Thorac Surg* 1980;32:386-391.
8. Karhunen JP, Jokinen JJ, Raivio PM, Salminen US. Long-term survival and quality of life after cardiac resuscitation following coronary artery bypass grafting. *Eur J Cardiothorac Surg* 2011;40:249-254.