

PERSPECTIVE

Massive Pneumoperitoneum after Bronchoscopy and Noninvasive Ventilation in a COVID-19 Patient, without Associated Pneumomediastinum or Pneumothorax

Maria Tudela¹, Maria Fernandez², Fernando Turegano³

ABSTRACT

The most common cause of pneumoperitoneum is a perforated hollow viscus. However, there are other causes that have been termed nonsurgical, asymptomatic, benign, or idiopathic pneumoperitoneum, most of them of thoracic origin; these are due to complications caused by invasive mechanical ventilation or interventional procedures such as fiberoptic bronchoscopy and are accompanied by pneumomediastinum, pneumothorax, or both. We present a case of isolated massive pneumoperitoneum, without accompanying pneumothorax or pneumomediastinum, in a patient with bilateral bronchopneumonia due to coronavirus disease 2019 (COVID-19) already cured and who underwent urgent bronchoscopy due to hemoptysis. This is a rather exceptional case due to barotrauma after noninvasive ventilation, and in whose pathophysiological mechanism both bronchoscopy and possible pulmonary fibrosis resulting from bilateral COVID-19 pneumonia may also have played a role.

Keywords: Barotrauma, Bilateral bronchopneumonia, COVID-19, Pathophysiological mechanism, Pneumoperitoneum, Pneumothorax.

RESUMEN

La causa más frecuente de neumoperitoneo es la perforación de una víscera hueca. Sin embargo, existen otras causas a las que se ha denominado neumoperitoneo no quirúrgico, asintomático, benigno o idiopático, entre las que destacan las de origen torácico; éstas se deben a una complicación de la ventilación mecánica invasiva o a procedimientos intervencionistas como la fibrobroncoscopia, y se acompañan de neumomediastino, neumotórax o de ambos. Presentamos un caso de neumoperitoneo aislado masivo, sin neumotórax ni neumomediastino acompañantes, en un paciente con bronconeumonía bilateral por Covid-19 ya curada y que fue sometido a fibrobroncoscopia urgente por hemoptisis. Se trata de un caso excepcional por el posible barotrauma tras ventilación no invasiva, y en cuyo mecanismo fisiopatológico pudieron estar implicados también la fibrobroncoscopia y la posible fibrosis pulmonar resultante de la neumonía bilateral por Covid-19.

Palabras clave: Barotrauma, Bronconeumonía bilateral, COVID-19, Mecanismo fisiopatológico, Neumoperitoneo, Neumotórax.

Panamerican Journal of Trauma, Critical Care & Emergency Surgery (2020): 10.5005/jp-journals-10030-1278

BACKGROUND

Up to 90% of cases of pneumoperitoneum are due to perforation of a hollow viscus. However, pneumoperitoneum can be produced by processes that do not require surgical treatment, the so-called benign, nonsurgical, idiopathic, or asymptomatic pneumoperitoneum. There are multiple causes that may lead to it, including the use of mechanical ventilation or interventional procedures such as bronchoscopy,¹ and they are almost always accompanied by pneumothorax and/or pneumomediastinum. Our aim in reporting this most unusual case was to briefly discuss its potential pathophysiology in the context of the current coronavirus disease 2019 (COVID-19) pandemic.

CASE DESCRIPTION

A 59-year-old man was brought into the emergency department (ED) due to an episode of moderate-to-severe hemoptysis. He was hemodynamically stable. His recent medical history included an admission for bilateral bronchopneumonia due to COVID-19, 3 weeks before. He recovered well and was eventually discharged with a SARS-CoV-2 negative status as confirmed by polymerase chain reaction. During that recent admission, he did not require any care by intensive care unit but was on noninvasive ventilation with high-flow oxygen. A chest computed tomography (CT) scan was not performed at the time. He was neither on anticoagulant

¹Department of Gastrointestinal Surgery, University General Hospital Gregorio Marañón, Madrid, Spain

^{2,3}Department of Emergency Surgery, University General Hospital Gregorio Marañón, Madrid, Spain

Corresponding Author: Maria Tudela, Department of Gastrointestinal Surgery, University General Hospital Gregorio Marañón, Madrid, Spain, Phone: +34 619552562, e-mail: matuler@hotmail.com

How to cite this article: Tudela M, Fernandez M, Turegano F. Massive Pneumoperitoneum after Bronchoscopy and Noninvasive Ventilation in a COVID-19 Patient, without Associated Pneumomediastinum or Pneumothorax. *Panam J Trauma Crit Care Emerg Surg* 2020;9(2): 162–164.

Source of support: Nil

Conflict of interest: None

medications nor had any previous history of gastroduodenal ulcer. He underwent an urgent fiberoptic bronchoscopy to determine the site of bleeding and this was performed with regular PPE, despite the previous negative COVID-19 test, in view of the rather high rate of false-negative tests we were seeing at the time. A negative pressure room was not used for the procedure. No active hemorrhage was found, and only traces of blood were evident in the distal tracheobronchial tree bilaterally. The procedure was carried

out under sedation that required noninvasive bag ventilation for a short period of time due to an episode of O₂ desaturation. During this ventilation, the patient developed a marked abdominal distension that seemed to increase with the bag insufflations, and had a very slow recovery of his O₂ saturation.

After the procedure, the patient was eupneic, without respiratory difficulty, with normal vital signs, and a 99% O₂ saturation. The abdomen was still very distended but without any pain or peritoneal signs. The blood test was completely normal, and an abdominal X-ray showed a marked pneumoperitoneum (Fig. 1). A thoracoabdominal CT scan without oral contrast was performed, which confirmed the massive pneumoperitoneum without any direct or indirect signs of perforation of a hollow viscus; residual ground-glass opacities and lung changes suggestive of fibrosis (Fig. 2), without any associated pneumothorax or pneumomediastinum, were also reported (Fig. 3). However, given the size of the pneumoperitoneum and its sudden appearance, an upper GI endoscopy was performed, which also ruled out esophageal, gastric, or duodenal perforation. It was decided to closely observe the patient, who remained asymptomatic and with no recurrence of his hemoptysis. There was a progressive radiological disappearance of the pneumoperitoneum over the following 4 days, and he was discharged home in a good condition.

DISCUSSION

Once a perforated viscus has been ruled out as the cause of pneumoperitoneum, the thoracic cavity is the most frequent source, having been described in association with CPR maneuvers, pulmonary parenchymal disease, pneumomediastinum, pneumothorax, blunt chest trauma, and use of invasive mechanical ventilation.¹ Pneumoperitoneum due to mechanical ventilation is a rare complication whose incidence is unknown, although it is estimated to occur in about 7% of patients with invasive ventilation.² Regarding noninvasive mechanical ventilation (NIMV), we were able to retrieve only four cases of pneumoperitoneum described in the literature.^{3–6} In addition to this, we believe that the interest of this case lies also in the recent history of bilateral bronchopneumonia secondary to COVID-19 infection, with presumed sequelae of lung fibrosis, and the confirmation by CT scan of the absence of associated radiological pneumothorax and/or

pneumomediastinum. Both the barotrauma secondary to NIMV and bronchoscopy could have been involved in the pathophysiological mechanism. This barotrauma usually causes pneumothorax. The occurrence of pneumomediastinum is explained by the so-called “Macklin effect,” by which air secondary to alveolar rupture spreads through the bronchovascular sheaths into the mediastinum. Air from the pleural space and/or mediastinum can spread to the abdominal cavity through small pleuroperitoneal anatomic defects, although the speed with which this massive pneumoperitoneum developed in our patient was puzzling at best, and made us rule out a gastroduodenal perforation despite the absolute lack of symptoms or any other evidence of an acute surgical condition.

With regard to bronchoscopy as a cause of asymptomatic pneumoperitoneum, it is extremely rare.⁷ It has been argued that the use of muscle relaxants in anesthesia, together with the increase in negative pressure in the esophagus during inspiration, could result in relaxation of the lower esophageal sphincter (LES) and the passage of air into the stomach during bronchoscopy, which could eventually result in a perforation of the lesser curve of the stomach, leading to symptomatic pneumoperitoneum. This was ruled out in our patient as described.

Regarding the history of infection by COVID-19, it is important to highlight, as already mentioned, that this bilateral bronchopneumonia may cause pulmonary fibrosis,⁸ possibly favoring the occurrence of barotrauma with less airway pressures. Also, a potential role of fibrosis of the diaphragm together with the bases of the lungs could theoretically add to the easier passage of air into the abdomen. The hemoptysis of this patient may have been caused by residual inflammation of his distal bronchial tree, although the bronchoscopy report was not conclusive in this respect.

As a last consideration, it is essential to point out that both bronchoscopy and noninvasive bag ventilation should be reduced to the essential minimum in COVID-19 patients (in our case already negative) due to the risk of aerosolization of the virus, and only performed in life-threatening situations such as severe hemoptysis or airway compromise.⁹

A massive pneumoperitoneum of the thoracic origin like the one in our case does not usually have clinical significance and can be managed by observation alone. However, the possible

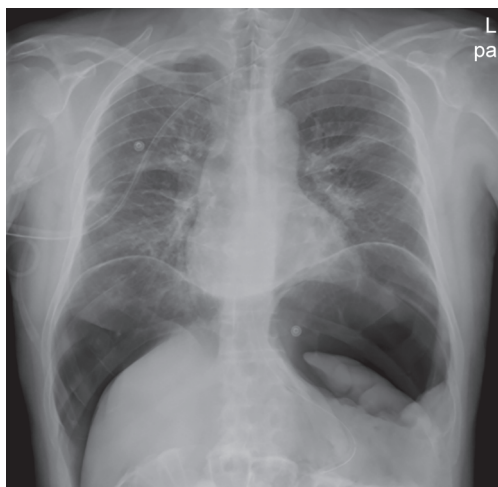


Fig. 1: Abdominal X-ray showed a massive pneumoperitoneum

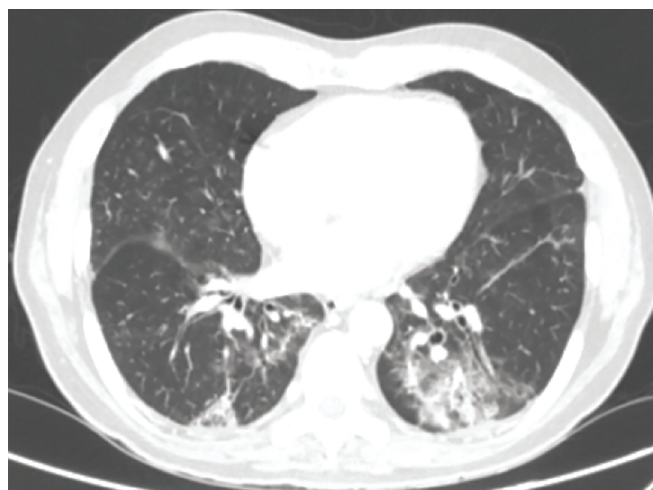


Fig. 2: Computed tomography scan section of the lower thorax showing the residual ground-glass opacities and lung changes suggestive of fibrosis

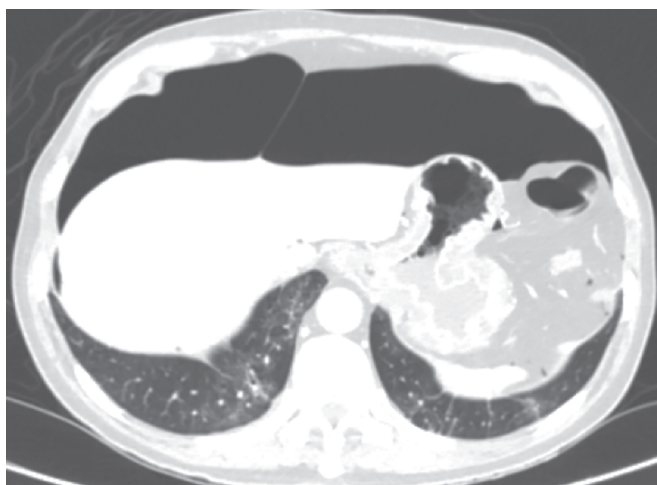


Fig. 3: Computed tomography scan section of the upper abdominal showing the pneumoperitoneum and the absence of associated pneumothorax or pneumomediastinum

appearance of an abdominal compartment syndrome should be monitored, which, being exceptional in this context, could force an air-evacuation procedure, as described in the literature.¹⁰ The intra-abdominal pressure of our patient was not measured, but he maintained a regular urine output and a normal respiratory rate and O₂ saturation until his discharge from the hospital.

In conclusion, pneumoperitoneum in patients without abdominal symptoms may be due to barotrauma secondary to noninvasive ventilation. Being this an exceptional but isolated case, one can only guess whether the probable pulmonary fibrosis secondary to recent bilateral COVID-19 pneumonia could have played a role. The absence of accompanying air in the mediastinum or pleural space is exceptional, as is its development after noninvasive ventilation; the likely iatrogenic role of bronchoscopy remains unknown in our case.

REFERENCES

1. Mularski RA, Sippel JM, Osborne ML. Pneumoperitoneum: a review of nonsurgical causes. *Crit Care Med* 2000;28(7):2638–2644. DOI: 10.1097/00003246-200007000-00078.
2. Okamoto A, Nakao A, Matsuda K, et al. Non-surgical pneumoperitoneum associated with mechanical ventilation. *Acute Med Surg* 2014;1(4):254–255. DOI: 10.1002/ams2.52.
3. Planchard D, Verdaguer M, Levrat V, et al. Pneumoperitoneum and pneumomediastinum complicating non-invasive ventilation. *Rev Mal Respir* 2005;22(1):147–150. DOI: 10.1016/s0761-8425(05)85446-4.
4. Olgemoller U, Korber W, Crie CP. Abdominal free air without signs of perforated abdominal viscus during non-invasive ventilation. *Dtsch Med Wochenschr* 2012;137(31-32):1591–1594. DOI: 10.1055/s-0032-1305183.
5. Wolfromm A, Weiss N, Espinoza S, et al. Non-invasive positive pressure ventilation (NIPPV)-induced pneumocephalus and pneumoperitoneum in a patient with a one-way flow control ventriculoperitoneal shunt. *Intensive Care Med* 2011;37(5):889–890. DOI: 10.1007/s00134-011-2191-7.
6. Vélez Silva R, Martínez Jiménez CH, Fernández Hurtado I. Neumoperitoneo como complicación de la ventilación mecánica, sin evidencia radiológica de neumotórax. *Emergencias* 2006;18:170–173.
7. Stahl DL, Richard KM, Papadimos TJ. Complications of bronchoscopy: a concise synopsis. *Int J Crit Illn Inj Sci* 2015;5(3):189–195. DOI: 10.4103/2229-5151.164995.
8. Venkataraman T, Frieman MB. The role of epidermal growth factor receptor (EGFR) signaling in SARS coronavirus-induced pulmonary fibrosis. *Antiviral Res* 2017;143:142–150. DOI: 10.1016/j.antiviral.2017.03.022.
9. Wahidi MM, Lamb C, Murgu S, et al. American association for bronchology and interventional pulmonology (AABIP) statement on the use of bronchoscopy and respiratory specimen collection in patients with suspected or confirmed COVID-19 infection. *J Bronchology Interv Pulmonol* 2020. DOI: 10.1097/LBR.0000000000000681.
10. García-Santos E, Puerto-Puerto A, Sánchez-García S, et al. Síndrome compartimental abdominal por neumoperitoneo a tensión secundario a barotrauma. Presentación de un caso. *Cirugía y Cirujanos* 2015;83(5):429–432. DOI: 10.1016/j.cir.2015.05.046.